



Protocol for the Examination of Specimens from Patients with Well-Differentiated Neuroendocrine Tumors (Carcinoid Tumors) of the Appendix

Version: 4.1.0.0

Protocol Posting Date: June 2021

CAP Laboratory Accreditation Program Protocol Required Use Date: March 2022

The changes included in this current protocol version affect accreditation requirements. The new deadline for implementing this protocol version is reflected in the above accreditation date.

For accreditation purposes, this protocol should be used for the following procedures AND tumor types:

Procedure	Description
Excision	Includes specimens designated appendectomy, and right hemicolectomy
Tumor Type	Description
Well differentiated neuroendocrine tumor	

This protocol is NOT required for accreditation purposes for the following:

Procedure
Biopsy
Primary resection specimen with no residual cancer (eg, following neoadjuvant therapy)
Recurrent tumor
Cytologic specimens

The following tumor types should NOT be reported using this protocol:

Tumor Type
Poorly differentiated neuroendocrine carcinomas (including small cell and large cell neuroendocrine carcinomas) (consider the Appendix Carcinoma protocol)
Goblet cell adenocarcinoma (consider the Appendix Carcinoma protocol)

Authors

Lawrence J. Burgart, MD*; William V. Chopp, MD*; Dhanpat Jain, MD*.

With guidance from the CAP Cancer and CAP Pathology Electronic Reporting Committees.

* Denotes primary author.

Accreditation Requirements

This protocol can be **utilized** for a variety of procedures and tumor types for clinical care purposes. For accreditation purposes, only the definitive primary cancer resection specimen is required to have the core and conditional data elements reported in a synoptic format.

- Core data elements are required in reports to adequately describe appropriate malignancies. For accreditation purposes, essential data elements must be reported in all instances, even if the response is “not applicable” or “cannot be determined.”
- Conditional data elements are only required to be reported if applicable as delineated in the protocol. For instance, the total number of lymph nodes examined must be reported, but only if nodes are present in the specimen.
- Optional data elements are identified with “+” and although not required for CAP accreditation purposes, may be considered for reporting as determined by local practice standards.

The use of this protocol is not required for recurrent tumors or for metastatic tumors that are resected at a different time than the primary tumor. Use of this protocol is also not required for pathology reviews performed at a second institution (ie, secondary consultation, second opinion, or review of outside case at second institution).

Synoptic Reporting

All core and conditionally required data elements outlined on the surgical case summary from this cancer protocol must be displayed in synoptic report format. Synoptic format is defined as:

- Data element: followed by its answer (response), outline format without the paired Data element: Response format is NOT considered synoptic.
- The data element should be represented in the report as it is listed in the case summary. The response for any data element may be modified from those listed in the case summary, including “Cannot be determined” if appropriate.
- Each diagnostic parameter pair (Data element: Response) is listed on a separate line or in a tabular format to achieve visual separation. The following exceptions are allowed to be listed on one line:
 - Anatomic site or specimen, laterality, and procedure
 - Pathologic Stage Classification (pTNM) elements
 - Negative margins, as long as all negative margins are specifically enumerated where applicable
- The synoptic portion of the report can appear in the diagnosis section of the pathology report, at the end of the report or in a separate section, but all Data element: Responses must be listed together in one location

Organizations and pathologists may choose to list the required elements in any order, use additional methods in order to enhance or achieve visual separation, or add optional items within the synoptic report. The report may have required elements in a summary format elsewhere in the report IN ADDITION TO but not as replacement for the synoptic report ie, all required elements must be in the synoptic portion of the report in the format defined above.

Summary of Changes

v 4.1.0.0

- General Reformatting
- Revised Margins Section
- Revised Lymph Nodes Section
- Added Distant Metastasis Section
- Removed pTX and pNX Staging Classification
- Modified Tumor Extent Question

Reporting Template

Protocol Posting Date: June 2021

Select a single response unless otherwise indicated.

CASE SUMMARY: (APPENDIX NEUROENDOCRINE TUMOR)

Standard(s): AJCC-UICC 8

SPECIMEN

Procedure

- Appendectomy
- Right hemicolectomy
- Other (specify): _____

TUMOR

Tumor Site (Note A)

- Proximal half of appendix: _____
- Distal half of appendix: _____
- Diffusely involving appendix: _____
- Appendix, not otherwise specified: _____
- Other (specify): _____

Histologic Type and Grade # (Notes B,C)

For poorly differentiated (high-grade) neuroendocrine carcinomas, the College of American Pathologists (CAP) checklist for carcinoma of the appendix should be used.

- G1, well-differentiated neuroendocrine tumor
- G2, well-differentiated neuroendocrine tumor
- G3, well-differentiated neuroendocrine tumor
- Other (specify): _____
- GX, well-differentiated neuroendocrine tumor, grade cannot be assessed
- Not applicable

+Histologic Type and Grade Comment: _____

Histologic Grade Determination (select all that apply)

Mitotic rate and / or Ki67 labeling index is required to determine histologic grade

- Mitotic rate (Note C)

Mitotic Rate#

Mitotic rate should be reported as number of mitoses per 2 mm², by evaluating at least 10 mm² in the most mitotically active part of the tumor (e.g., if using a microscope with a field diameter of 0.55 mm, count 42 high power fields (10 mm²) and divide the resulting number of mitoses by 5 to determine the number of mitoses per 2 mm² needed to assign tumor grade).

- Specify number of mitoses per 2 mm²: _____ mitoses per 2 mm²
- Less than 2 mitoses per 2 mm²
- 2 to 20 mitoses per 2 mm²
- Greater than 20 mitoses per 2 mm²
- Cannot be determined (explain): _____
- Not applicable

AND/OR

- Ki-67 labeling index

Ki-67 Labeling Index

- Specify Ki-67 percentage: _____ %
- Less than 3%
- 3% to 20%
- Greater than 20%
- Cannot be determined (explain): _____
- Not applicable

Tumor Size (Note D)

- Greatest dimension in Centimeters (cm): _____ cm
- +Additional Dimension in Centimeters (cm): _____ x _____ cm**
- Cannot be determined (explain): _____

Tumor Extent

- Invades lamina propria
- Invades submucosa
- Invades muscularis propria
- Invades subserosa or mesoappendix without involvement of visceral peritoneum
- Perforates visceral peritoneum (serosa)
- Directly invades other adjacent organ(s) or structure(s) (e.g., abdominal wall, skeletal muscle) excluding direct mural extension to adjacent subserosa of adjacent bowel (specify): _____
- Cannot be determined: _____
- No evidence of primary tumor

Lymphovascular Invasion

- Not identified
- Present
- Cannot be determined: _____

+Perineural Invasion

- Not identified
- Present
- Cannot be determined: _____

+Tumor Comment: _____

MARGINS (Note E)

Margin Status

- All margins negative for tumor
- +Closest Margin(s) to Tumor (select all that apply)**
- Proximal: _____
- Distal: _____
- Radial or mesenteric: _____
- Other (specify): _____
- Cannot be determined: _____
- +Distance from Tumor to Closest Margin**
- Specify in Centimeters (cm)*
- Exact distance in cm: _____ cm
- Greater than 1 cm

Specify in Millimeters (mm)

Exact distance in mm: _____ mm

Greater than 10 mm

Other

Other (specify): _____

Cannot be determined: _____

Tumor present at margin

Margin(s) Involved by Tumor (select all that apply)

Proximal: _____

Distal: _____

Radial or mesenteric: _____

Other (specify): _____

Cannot be determined: _____

Other (specify): _____

Cannot be determined (explain): _____

Not applicable

+Margin Comment: _____

REGIONAL LYMPH NODES

Regional Lymph Node Status

Not applicable (no regional lymph nodes submitted or found)

Regional lymph nodes present

All regional lymph nodes negative for tumor

Tumor present in regional lymph node(s)

Number of Lymph Nodes with Tumor

Exact number (specify): _____

At least (specify): _____

Other (specify): _____

Cannot be determined (explain): _____

Other (specify): _____

Cannot be determined (explain): _____

Number of Lymph Nodes Examined

Exact number (specify): _____

At least (specify): _____

Other (specify): _____

Cannot be determined (explain): _____

+Regional Lymph Node Comment: _____

DISTANT METASTASIS

Distant Site(s) Involved, if applicable (select all that apply)

Not applicable

Liver: _____

Lung: _____

Ovary: _____

Nonregional lymph node(s): _____

Peritoneum: _____

Bone: _____
 Other (specify): _____
 Cannot be determined: _____

PATHOLOGIC STAGE CLASSIFICATION (pTNM, AJCC 8th Edition) (Note F)

Reporting of pT, pN, and (when applicable) pM categories is based on information available to the pathologist at the time the report is issued. As per the AJCC (Chapter 1, 8th Ed.) it is the managing physician's responsibility to establish the final pathologic stage based upon all pertinent information, including but potentially not limited to this pathology report.

TNM Descriptors (select all that apply)

Not applicable
 m (multiple primary tumors)
 r (recurrent)
 y (post-treatment)

pT Category

pT not assigned (cannot be determined based on available pathological information)
 pT0: No evidence of primary tumor
 pT1: Tumor 2 cm or less in greatest dimension
 pT2: Tumor more than 2 cm but less than or equal to 4 cm
 pT3: Tumor more than 4 cm or with subserosal invasion or involvement of the mesoappendix
 pT4: Tumor perforates the peritoneum or directly invades other adjacent organs or structures (excluding direct mural extension to adjacent subserosa of adjacent bowel), e.g., abdominal wall and skeletal muscle

pN Category

pN not assigned (no nodes submitted or found)
 pN not assigned (cannot be determined based on available pathological information)
 pN0: No regional lymph node metastasis
 pN1: Regional lymph node metastasis

pM Category (required only if confirmed pathologically)

Not applicable - pM cannot be determined from the submitted specimen(s)
pM1: Distant metastasis
 pM1a: Metastasis confined to liver
 pM1b: Metastasis in at least one extrahepatic site (e.g., lung, ovary, nonregional lymph node, peritoneum, bone)
 pM1c: Both hepatic and extrahepatic metastases
 pM1 (subcategory cannot be determined)

ADDITIONAL FINDINGS (Note G)

+Additional Findings (select all that apply)

None identified
 Tumor necrosis
 Acute appendicitis
 Other (specify): _____

COMMENTS

Comment(s): _____

Explanatory Notes

A. Application and Tumor Location

This protocol applies to well-differentiated neuroendocrine tumors (carcinoid tumors) of the appendix of any size. For poorly differentiated neuroendocrine carcinomas (including small cell carcinomas and large cell neuroendocrine carcinomas) and goblet cell adenocarcinoma (previously goblet cell carcinoid tumor), use the CAP cancer protocol for carcinoma of the appendix¹.

The appendix is a common site of gastrointestinal neuroendocrine tumors, usually presenting as small solitary lesions incidentally discovered after appendectomy. Appendiceal neuroendocrine tumors are commonly diagnosed at a young age and arise in the deep mucosa or submucosa. Unlike other gastrointestinal neuroendocrine tumors or appendiceal adenocarcinomas, tumor size is considered more important than depth of invasion for appendiceal neuroendocrine tumor. Therefore, the staging system for appendiceal neuroendocrine tumors is different from those for other neuroendocrine tumors of the gut.²

References

1. Kakar S, Shi C, Driman DK, et al. Protocol for the Examination of Specimens From Patients With Carcinoma of the Appendix. 2017. Available at www.cap.org/cancerprotocols.
2. Amin MB, Edge SB, Greene FL, et al, eds. *AJCC Cancer Staging Manual*. 8th ed. New York, NY: Springer; 2017.

B. Histologic Type

Most appendiceal NETs are low grade, with none to few mitoses and no necrosis, and have traditionally been classified as “carcinoids.” Although the term “carcinoid tumor” remains in widespread use, this term may cause confusion for clinicians, who might view a carcinoid tumor as a serotonin-producing tumor associated with functional manifestations of carcinoid syndrome. The use of the term “carcinoid” for neuroendocrine tumor reporting is therefore discouraged for these reasons.

Immunohistochemistry and other ancillary techniques are generally not required to diagnose well-differentiated neuroendocrine tumors. Specific markers that may be used to establish neuroendocrine differentiation include chromogranin A, synaptophysin, and CD56.¹ Because of their relative sensitivity and specificity, chromogranin A and synaptophysin are recommended.

Although specific histologic patterns in well-differentiated neuroendocrine tumors, such as trabecular, insular, and glandular, roughly correlate with tumor location,² these patterns have not been clearly shown independently to predict response to therapy or risk of nodal metastasis and are rarely reported in clinical practice. Most appendiceal neuroendocrine tumors are derived from enterochromaffin cells. Rarely, L-cell neuroendocrine tumors of the appendix are encountered; because of their distinctive growth pattern of tear-drop-shaped tubules embedded in a fibrous stroma,³ these lesions are sometimes called tubular neuroendocrine tumors. It should be noted that these tumors are negative for chromogranin A but express enteroglucagon, peptide YY, and pancreatic polypeptide. Tubular neuroendocrine tumors are usually small lesions confined to the appendix and are found in female patients. These lesions exhibit benign behavior and should not be confused with adenocarcinoma.

References

1. Williams GT. Endocrine tumours of the gastrointestinal tract: selected topics. *Histopathology*. 2007;50(1):30-41.
2. Soga J. Carcinoids of the colon and ileocecal region: a statistical evaluation of 363 cases collected from the literature. *J Exp Clin Cancer Res*. 1998;17(2):139-148.

3. Iwafuchi M, Watanabe H, Ajioka Y, Shimoda T, Iwashita A, Seiki I. Immunohistochemical and ultrastructural studies of twelve argentaffin and six argyrophil carcinoids of the appendix vermiformis. *Hum Pathol.* 1990;21(7):773-780.

C. Histologic Grade

Cytologic atypia in well differentiated neuroendocrine tumors has no impact on clinical behavior of these tumors. The WHO classification¹ and others² use mitotic rate and/or Ki-67 index as one of the criteria for potential for aggressive behavior. Mitotic rate should be reported as number of mitoses per 2 mm², by evaluating at least 10mm² in the most mitotically active part of the tumor. Only clearly identifiable mitotic figures should be counted; hyperchromatic, karyorrhectic, or apoptotic nuclei are excluded. Because of variations in field size, the number of high-power fields (HPF) (at 40X magnification) for 10 mm² (thereby 2 mm²) must be determined for each microscope (Table 1). For example, if using a microscope with a field diameter of 0.55 mm, count 42 HPF and divide the resulting number of mitoses by 5 to determine the number of mitoses per 2 mm² needed to assign tumor grade.

Table 1. Number of HPF Required for 10 mm² Using Microscopes With Different Field Diameter

Field Diameter (mm)	Area (mm ²)	Number of HPF for 10 mm ²
0.40	0.125	80
0.41	0.132	75
0.42	0.139	70
0.43	0.145	69
0.44	0.152	65
0.45	0.159	63
0.46	0.166	60
0.47	0.173	58
0.48	0.181	55
0.49	0.189	53
0.50	0.196	50
0.51	0.204	49
0.52	0.212	47
0.53	0.221	45
0.54	0.229	44
0.55	0.238	42
0.56	0.246	41
0.57	0.255	39
0.58	0.264	38
0.59	0.273	37
0.60	0.283	35
0.61	0.292	34
0.62	0.302	33
0.63	0.312	32
0.64	0.322	31
0.65	0.332	30
0.66	0.342	29
0.67	0.353	28
0.68	0.363	28
0.69	0.374	28

Ki-67 index is reported as percent positive tumor cells in area of highest nuclear labeling (“hot spot”), although the precise method of assessment has not been standardized. A number of methods have used to assess Ki-67 index, including automatic counting and “eyeballing”.^{3,4} Automated counting is not widely available and requires careful modification of the software to circumvent the inaccuracies.³ Eye-balling can be used for most tumors; however, for tumors with Ki-67 index close to grade cut-offs, it is recommended to perform the manual count on the print of camera-captured image of the hot spot. It has

been recommended that a minimum of 500 tumor cells be counted to determine the Ki-67 index, and a notation is made if less cells are available. Grade assigned based on Ki-67 index is typically higher than that based on mitotic count, and the case is assigned to the higher of the 2 if both methods are performed.¹

It is important to note that there are a small group of well-differentiated neuroendocrine tumors with a Ki-67 index >20% and a mitotic rate usually <20 per 10 HPF. In WHO-2010, these tumors were considered as G3 poorly differentiated neuroendocrine carcinomas. However, they have typical morphology of well-differentiated tumors.

Previous studies (most on pancreatic neuroendocrine tumors) have demonstrated that these tumors have a worse prognosis than grade 2 (Ki-67=3-20 % and mitosis <20/10 HPF) neuroendocrine tumors, but they are not as aggressive as poorly differentiated neuroendocrine carcinomas.⁵ In addition, these tumors do not have the genetic abnormalities seen in poorly differentiated neuroendocrine carcinomas.⁶ Furthermore, unlike poorly differentiated neuroendocrine carcinomas, they are less responsive to platinum-based chemotherapy.⁷ In the WHO-2019 blue book of digestive system tumors and AJCC 8th edition, those with typical morphology of well-differentiated tumors are classified as “well-differentiated neuroendocrine tumor” but as grade 3 (Table 2).^{1,8}

Table 2 Recommended Grading System for Well-Differentiated Gastroenteropancreatic Neuroendocrine Tumors

Grade	Mitotic Rate (per 2mm ²)	Ki-67 index (%)
Well-differentiated neuroendocrine tumor, G1	<2	<3
Well-differentiated neuroendocrine tumor, G2	2-20	3-20
Well-differentiated neuroendocrine tumor, G3	>20	>20

References

1. WHO Classification of Tumours Editorial Board. *Digestive system tumours*. Lyon (France): International Agency for Research on Cancer; 2019. (WHO classification of tumours series, 5th ed.; vol. 1).
2. Rindi G, Kloppel G, Alhman H, et al; and all other Frascati Consensus Conference participants; European Neuroendocrine Tumor Society (ENETS). TNM staging of foregut (neuro)endocrine tumors: a consensus proposal including a grading system. *Virchows Arch*. 2006;449(4):395-401.
3. Tang LH, Gonen M, Hedvat C, Modlin I, Klimstra DS. Objective quantification of the Ki67 proliferative index in neuroendocrine tumors of gastroenteropancreatic system: a comparison of digital image analysis with manual methods. *Am J Surg Pathol*. 2012;36(12):1761-1770.
4. Reid MD, Bagci P, Ohike N, et al. Calculation of the Ki67 index in pancreatic neuroendocrine tumors: a comparative analysis of four counting methodologies. *Mod Pathol*. 2016;29(1):93.
5. Shi C, Klimstra DS. Pancreatic neuroendocrine tumors: pathologic and molecular characteristics. *Semin Diagn Pathol*. 2014;31(6):498-511.
6. Yachida S, Vakiani E, White CM, Zhong Y, Saunders T, Morgan R et al. Small cell and large cell neuroendocrine carcinomas of the pancreas are genetically similar and distinct from well-differentiated pancreatic neuroendocrine tumors. *Am J Surg Pathol*. 2012;36(2):173-184.
7. Sorbye H, Strosberg J, Baudin E, Klimstra DS, Yao JC. Gastroenteropancreatic high-grade neuroendocrine carcinoma. *Cancer*. 2014;120(18):2814-2823.
8. Amin MB, Edge SB, Greene FL, et al, eds. *AJCC Cancer Staging Manual*. 8th ed. New York, NY: Springer; 2017.

D. Tumor Size

Appendiceal neuroendocrine tumors smaller than 1.0 cm do not recur or metastasize, whereas those between 1.0 and 2.0 cm rarely do.¹ Tumor size >2.0 cm and mesoappendiceal invasion² have been correlated with nodal metastasis, but not with poor outcome.³ For these reasons, appendectomy is

usually sufficient for tumors 1.0 cm or smaller, as well as many tumors between 1.0 and 2.0 cm. More extensive procedures (eg, right hemicolectomy) are usually reserved for patients with tumors larger than 2.0 cm or with invasion beyond the muscularis propria.

References

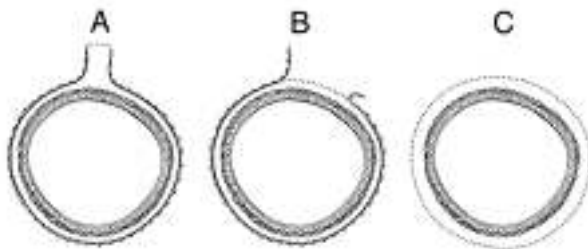
1. Carr NJ, Sobin LH. Neuroendocrine tumors of the appendix. *Semin Diagn Pathol.* 2004;21(2):108-119.
2. Syracuse DC, Perzin KH, Price JB, Wiedel PD, Mesa-Tejada R. Carcinoid tumors of the appendix: mesoappendiceal extension and nodal metastases. *Ann Surg.* 1979;190(1):58-63.
3. Rossi G, Valli R, Bertolini F, et al. Does mesoappendix infiltration predict a worse prognosis in incidental neuroendocrine tumors of the appendix?: a clinicopathologic and immunohistochemical study of 15 cases. *Am J Clin Pathol.* 2003;120(5):706-711.

E. Margins

Margins in a simple appendectomy specimen include the proximal and circumferential (radial) margin. It is recommended that the proximal margin on a simple appendectomy specimen should be taken en face in order to evaluate the entire appendiceal mucosa and muscularis circumferentially. In the vast majority of cases, the appendix is entirely peritonealized (Figure, A), and the closest distance between the tumor and the mesoappendiceal resection margin represents the radial margin and should be measured. Even retrocecal appendices are usually invested by peritoneum but have adhered to the posterior cecum, either because of inflammation or tumor. Exceptionally, a retrocecal appendix may be retroperitoneal, in which case the distance between the tumor and the nonperitonealized radial resection margin is the “surgical clearance” and should be measured.

In general, the circumferential (radial) margin must be assessed for any segment of gastrointestinal tract either incompletely encased or unencased by peritoneum (Figure, B and C). The posterior surface of the ascending colon portion of a right hemicolectomy specimen lacks a peritoneal covering and thus constitutes a circumferential margin, which in rare cases may be relevant in right hemicolectomy specimens resected for treatment of appendiceal neuroendocrine tumors. The circumferential (radial) margin represents the adventitial soft tissue margin closest to the deepest penetration of tumor and is created surgically by blunt or sharp dissection of the retroperitoneal or subperitoneal aspect, respectively. The distance between the tumor and circumferential (radial) margin should be reported, if applicable. The circumferential (radial) margin is considered positive if the tumor is present at the inked nonperitonealized surface. This assessment includes tumor within a lymph node as well as direct tumor extension, but if circumferential (radial) margin positivity is based solely on intranodal tumor, this should be so stated.

The mesenteric resection margin is the only relevant circumferential margin in segments completely encased by peritoneum (eg, cecum; mesoappendiceal resection margin for the appendix) (Figure, A). Involvement of this margin should be reported even if tumor does not penetrate the serosal surface.



A, Mesenteric margin in viscus completely encased by peritoneum (dotted line). B, Circumferential (radial) margin (dotted line) in viscus incompletely encased by peritoneum. C, Circumferential (radial) margin (dotted line) in viscus completely unencased by peritoneum.

F. Pathologic Stage Classification

The TNM staging system for appendiceal NETs of the American Joint Committee on Cancer (AJCC) and the International Union Against Cancer (UICC) is recommended.¹

pTNM Pathologic Classification

The pT, pN, and pM categories correspond to the T, N, and M categories except that pM0 (no distant metastasis) does not exist as a category.

By AJCC/UICC convention, the designation “T” refers to a primary tumor that has not been previously treated. The symbol “p” refers to the pathologic classification of the TNM, as opposed to the clinical classification, and is based on gross and microscopic examination. pT entails a resection of the primary tumor or biopsy adequate to evaluate the highest pT category, pN entails removal of nodes adequate to validate lymph node metastasis, and pM implies microscopic examination of distant lesions. Clinical classification (cTNM) is usually carried out by the referring physician before treatment during initial evaluation of the patient or when pathologic classification is not possible.

Pathologic staging is usually performed after surgical resection of the primary tumor. Pathologic staging depends on pathologic documentation of the anatomic extent of disease, whether or not the primary tumor has been completely removed. If a biopsied tumor is not resected for any reason (eg, when technically unfeasible) and if the highest T and N categories or the M1 category of the tumor can be confirmed microscopically, the criteria for pathologic classification and staging have been satisfied without total removal of the primary cancer.

TNM Descriptors

For identification of special cases of TNM or pTNM classifications, the “m” suffix and “y,” “r,” and “a” prefixes are used. Although they do not affect the stage grouping, they indicate cases needing separate analysis.

The “m” suffix indicates the presence of multiple primary tumors in a single site and is recorded in parentheses: pT(m)NM.

The “y” prefix indicates those cases in which classification is performed during or following initial multimodality therapy (ie, neoadjuvant chemotherapy, radiation therapy, or both chemotherapy and radiation therapy). The cTNM or pTNM category is identified by a “y” prefix. The ycTNM or ypTNM categorizes the extent of tumor actually present at the time of that examination. The “y” categorization is not an estimate of tumor prior to multimodality therapy (ie, before initiation of neoadjuvant therapy).

The “r” prefix indicates a recurrent tumor when staged after a documented disease-free interval, and is identified by the “r” prefix: rTNM.

The “a” prefix designates the stage determined at autopsy: aTNM.

T Category Considerations

Tumor that is adherent to other organs or structures, macroscopically, is classified cT4. However, if no tumor is present in the adhesion and there is no serosal penetration microscopically, the classification should be pT1 to pT3.

N Category Considerations

The regional lymph nodes for the appendix are the ileocolic lymph nodes. pN0. Histologic examination of

a regional lymphadenectomy specimen will ordinarily include 12 or more lymph nodes. If the lymph node results are negative, but the number ordinarily examined is not met, classify as pN0.

References

1. Amin MB, Edge SB, Greene FL, et al, eds. *AJCC Cancer Staging Manual*. 8th ed. New York, NY: Springer; 2017.

G. Additional Findings

Coagulative tumor necrosis, usually punctate, may indicate more aggressive behavior¹ and should be reported. Appendiceal NETs are often an incidental finding in specimens removed for acute appendicitis.

References

1. Rindi G, Kloppel G, Couvelard A, et al. TNM staging of midgut and hindgut (neuro) endocrine tumors: a consensus proposal including a grading system. *Virchows Arch*. 2007;451(4):757-762.